

# Assessing Mepilex® Border in post-operative wound care

Tiina Pukki, Minna Tikkanen, Sirpa Halonen

## Abstract

**Aims:** An important component of surgical wound management is the selection of suitable dressings, especially for wounds with post-operative complications. The aim of this study was to survey the opinions of surgical nurses on the efficacy of Mepilex® Border (Mölnlycke Health Care) in the post-operative treatment of surgical wounds healing by primary intention, compared with previous dressing regimens. **Method:** This study used a questionnaire designed to establish the suitability and performance of Mepilex Border in the treatment of exuding surgical wounds healing by primary intention. The questionnaire was distributed to 300 surgical nurses in three Finnish hospitals. The response rate of the survey was 38%. **Results:** The 113 surgical nurses who responded to the questionnaire found Mepilex Border easy to use with excellent performance characteristics. **Conclusions:** The results of this survey demonstrate that surgical nurses found the performance of Mepilex Border to be superior in the treatment of surgical wounds when compared to previous dressing regimens. **Conflict of interest:** This survey was funded by Mölnlycke Health Care (Gothenburg, Sweden).

## KEY WORDS

Surgical wounds  
Dressings  
Primary intention  
Wound management

A wound that results from surgery is generally considered to be 'clean' and as a result is often judged as less of a clinical challenge than some other wound types. Most surgical wounds heal by primary intention, with the margins of the surgical incision closed using either stitches or clips. These are left in place until the edges heal (Vermeulen et al, 2007).

However, in certain circumstances, such as bacterial contamination of the wound or the presence of devitalised

tissue, wounds can be deliberately left open after an operation, either to be sutured at a later date (delayed primary closure), or left to heal naturally by secondary intention.

The key aims of surgical wound management should be to minimise physical trauma to the wound, prevent microbial invasion and ensure patient comfort. Unfortunately, post-operative complications do occur, especially in wounds healing by secondary intention, and the most common complication is an infection within the wound.

The challenges posed by post-operative wounds include:

- ▶▶ High levels of exudate and the potential risk of erythema, skin maceration, and skin blistering
- ▶▶ Increased levels of pain, which may have a negative impact on healing rates and a patient's quality of life
- ▶▶ Extended hospital stays (i.e. as a consequence of a surgical site infection), which involve increased costs to the healthcare provider as well as socioeconomic implications for the patient.

The main functions of surgical

dressings are to allow post-operative assessment of the wound, absorb exudate, ease pain and provide protection for newly formed tissue (Baxter, 2003).

Dressings also need to maintain an optimal moist wound environment, without causing maceration of the surrounding skin (National Institute for Health and Clinical Excellence [NICE], 2008). Therefore, the selection of suitable dressings for the treatment of surgical wounds is an extremely important component of surgical wound care management.

## Complications

The adherence of a dressing to a wound bed can result in unnecessary trauma and pain during removal (Hollinworth and Collier, 2000). Similarly, the repeated application and removal of an adhesive dressing can cause epidermal stripping of the skin surrounding the wound (Cutting, 2008).

Adhesive-induced skin damage may lead to inflammatory reactions, oedema and soreness, which can have a detrimental effect on the barrier function of the skin (Dykes et al, 2001).

Tiina Pukki is an Authorised TVN at Meilahti Hospital;  
Minna Tikkanen is an Authorised TVN at Töölö Hospital;  
and Sirpa Halonen is an Authorised TVN at Jorvi Hospital,  
Hospital District of Helsinki and Uusimaa, Finland

In addition, the continued friction to the skin brought on by repeated wound dressings plays a major role in the development of post-operative skin blisters, a common complication following surgical procedures, especially in hip and knee surgery (Wright, 1994; Hahn et al, 1999; Jester et al, 2000; Gupta et al, 2002; Lawrentschuk et al, 2002; Koval et al, 2003; Cosker et al, 2005; Abuzakuk et al, 2006; Ravenscroft et al, 2006).

Adhesive dressings that lack elasticity or those that have been applied too tightly can create tension at the dressing/skin interface (Blaylock et al, 1995; Gupta et al, 2002; Koval et al, 2003). Skin blisters often develop at the point of dressing adherence, generally on the peri-wound skin if island dressings are being used, and can result in increased pain, delayed healing and an increased susceptibility to infection.

Post-operative wound oedema and/or physical movement increase this tension, which can result in trauma to the epidermis and the formation of blisters (Blaylock et al, 1995; Lawrentschuk et al, 2002). These blisters may subsequently require additional dressings, with a concomitant increase in nursing time as well as delayed hospital discharge (Gupta et al, 2002).

Unfortunately, in recent years, despite these complications and their attendant costs, the majority of wound dressing development has been directed towards chronic wounds, with the development of surgical dressings being relatively overlooked.

### Safetac®

It has been reported that modern wound dressing types (alginates, films, foams, hydrocolloids and hydrogels) have the propensity to cause pain and tissue trauma during dressing changes (Hollinworth and Collier, 2000), although the introduction of a range of dressings utilising Safetac® (Mölnlycke Health Care) adhesive technology has helped to overcome these issues.

Safetac is a patented technology that involves the use of soft silicone, a material that readily adheres to intact dry skin and can remain *in situ* on the surface of

a moist wound or damaged peri-wound skin without adhering to the fragile tissue.

Soft silicone adhesives are described as micro-adherent as they create many contact points over the uneven surface of the skin. They exist in a permanent 'tacky' state to provide a safe level of adhesion, which does not increase on contact with the skin over time (Rippon and White, 2007).

### Soft silicone adhesives are described as micro-adherent as they create many contact points over the uneven surface of the skin.

Consequently, dressings with wound contact surfaces incorporating Safetac can be applied repeatedly without causing damage to the wound or any stripping of the epidermis in the peri-wound region (Cutting, 2008). Furthermore, the seal that forms between the intact skin and a dressing with Safetac inhibits the movement of exudate from the wound onto the surrounding skin, thereby helping to prevent maceration of the peri-wound area (White, 2005).

Several clinical evaluations have demonstrated that dressings with Safetac are beneficial in the management of surgical wounds and their complications; they provide environments that are conducive to healing, prevent dressing-related trauma and minimise dressing-related pain (Burton, 2004; Gleaves and Eldridge, 2004; Weaver and Crawford, 2007; Meuleneire et al, 2008).

### Mepilex® Border

Mepilex® Border (Mölnlycke Health Care) is an all-in-one island dressing that consists of:

- » A perforated Safetac wound contact layer
- » An absorbent pad
- » An outer vapour-permeable waterproof film.

Mepilex Border is designed to absorb exudate, maintain a moist wound-healing environment and minimise the risk of

maceration in a wide variety of wound types, including surgical wounds.

In order to assess the clinical effectiveness of Mepilex Border in treating surgical wounds, a retrospective survey of nurse practitioners was undertaken (funded by Mölnlycke Health Care).

### Aims

The objective of this survey was to determine the effectiveness of Mepilex Border (surgical sizes) in the treatment of surgical wounds healing by primary intention and to compare this to previous dressing regimens.

### Methods

The opinions and experiences of nurse practitioners from three Finnish hospitals (where the study investigators are based) on the use of Mepilex Border were sought. A questionnaire, similar to ones that have previously been used by the practitioners to evaluate wound dressings in their respective hospitals, was used as a basis to establish:

- » The suitability of the Mepilex Border sizes available for the treatment of exuding surgical wounds healing by primary intention
- » The performance of Mepilex Border in the treatment of surgical wounds as compared to either basic or combination dressing regimens.

The questionnaire was designed to capture the following information:

- » Specialties of the survey participants
- » Surgical wound types treated with the dressing
- » Sizes of dressing used and their suitability
- » Ease of application and removal (rated as either 'very easy', 'easy', 'difficult' or 'very difficult')
- » Dressing absorbency, elasticity and 'stay-on' ability (rated as either 'very good', 'good', 'bad' or 'very bad')
- » Occurrence of peri-wound skin reactions
- » Overall experience of using dressing (rated as 'excellent', 'good', 'average' or 'bad').

The authors acted as nurse coordinators for the study at their respective hospitals. Each

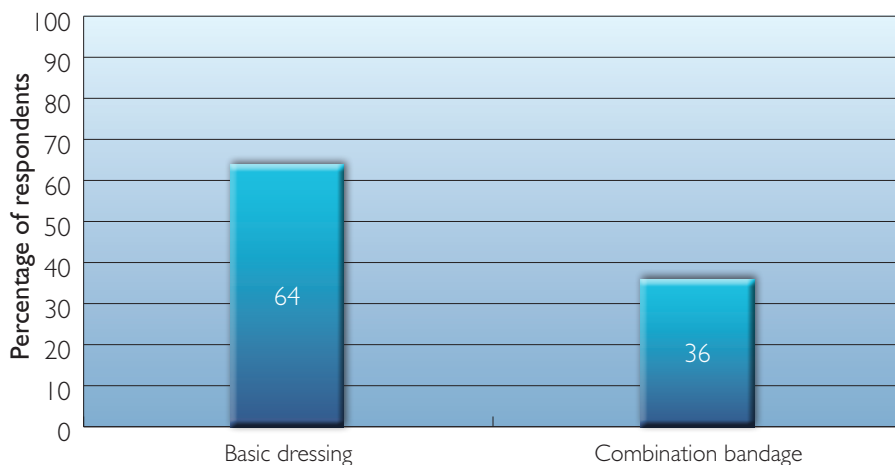
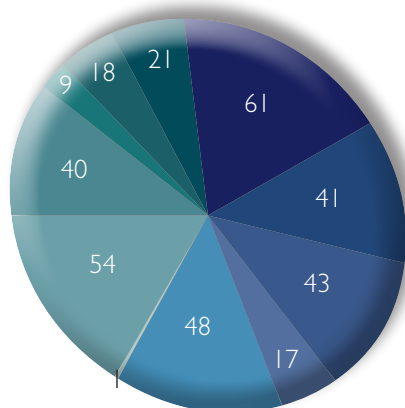


Figure 1. The types of dressings previously used by the nurse practitioners to dress surgical wounds.

nurse coordinator distributed 100 questionnaires during April and May 2009 to nurses based in various surgical (gastroenterology, orthopaedics, plastics, vascular) and intensive care departments — a total of 300 questionnaires were handed out.

Instructions on how to complete the questionnaires were also issued to the nurses. Only those with experience of



- Hip
- Knee
- Vascular
- Cardiothoracic
- Shoulder
- C-section
- Laparotomy
- Back
- Breast
- Inguinal hernia
- Other

Figure 2. The range of surgical wounds treated with Mepilex Border before the survey was undertaken (figures represent patient numbers).

using Mepilex Border on exuding surgical wounds healing by primary intention were allowed to participate in the survey.

The response rate to the questionnaire was 38% and the results were analysed between June and August 2009 by the nurse coordinators.

Data from the completed questionnaires were entered onto a Microsoft Excel spreadsheet and the results presented graphically.

As this study was designed as a retrospective survey of nurses' experiences and did not involve the assessment of individual patients, there was no requirement to obtain research ethics approval.

## Results

### Evaluation of dressing size

A total of 113 nurse practitioners from

several specialities including vascular surgery, plastic surgery, orthopaedics, gastroenterology surgery and intensive care, with different levels of experience (ranging from days to months) of using Mepilex Border participated in this survey.

All of the participants had previously used either a basic (one-layer) dressing (i.e. island-type dressing with traditional adhesives), or a combination bandage to dress surgical wounds. The types of dressing previously used are presented in Figure 1.

The survey revealed that, prior to their participation in the survey, the nurse practitioners had used Mepilex Border on a wide variety of surgical wounds (Figure 2). The two available sizes (10x20cm and 10x30cm) had been used in approximately equal numbers and 89% of respondents felt that the range of sizes available was adequate.

However, 66% of the nurses did report that they had used an extra, traditional-sized Mepilex Border dressing to 'extend' the size of a Mepilex Border (surgical) dressing. Both size of dressing exhibited excellent retention. Of those surveyed, all rated the 'stay-on' ability of the dressing as either 'excellent' (31%) or 'good' (69%).

### Dressing performance

All of the nurses surveyed found Mepilex Border either easy (58%) or very easy (42%) to apply (Figure 3). Similarly,

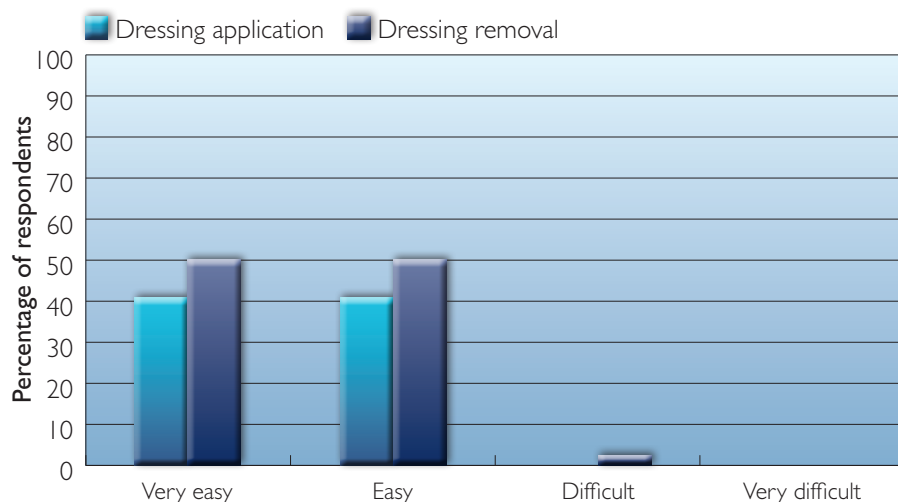


Figure 3. The ease of application and removal of Mepilex Border.

dressing removal was found to be easy or very easy by 48% and 50% of the nurses, respectively (Figure 3).

The absorbance capacity of Mepilex Border was reported to be excellent, with 100% of the nurses evaluating it as good or very good (Figure 4). In addition, the nurses found the elasticity of Mepilex Border when in contact with the skin to be either good (48%) or very good (50%) (Figure 5).

It was felt by 99% of respondents that elasticity was an important requirement in a dressing designed to maintain the integrity of the peri-wound skin and prevent wound complications (Figure 6).

The majority of the nurses (91%) noticed a decrease in detrimental peri-wound skin reactions following the use of Mepilex Border compared to previous dressing regimens. Of the respondents, 40% considered this decrease to be significant (Figure 7).

Overall, all the nurses rated their experience of using Mepilex Border to treat a surgical wound as either good (34%) or excellent (66%) (Figure 8).

The dressing's overall performance was rated as better (57%) or much better (40%) than other dressing regimens the nurses had used (Figure 9).

Discussion

Infection, pain and delayed healing in surgical wounds present a considerable challenge for clinicians. However, although infection is arguably the most recognised surgical wound complication, it is extremely important that clinicians also take steps to prevent post-operative blistering of the peri-wound skin.

The majority of surgical wounds are closed during the immediate post-operative period (Dealey,1994). Those wounds that are left open to heal by secondary intention due to contamination or infection (Marks et al, 1985) were traditionally packed with a simple dressing, such as ribbon gauze soaked in saline or antiseptic, which was applied in theatre (Foster and Moore, 1997).

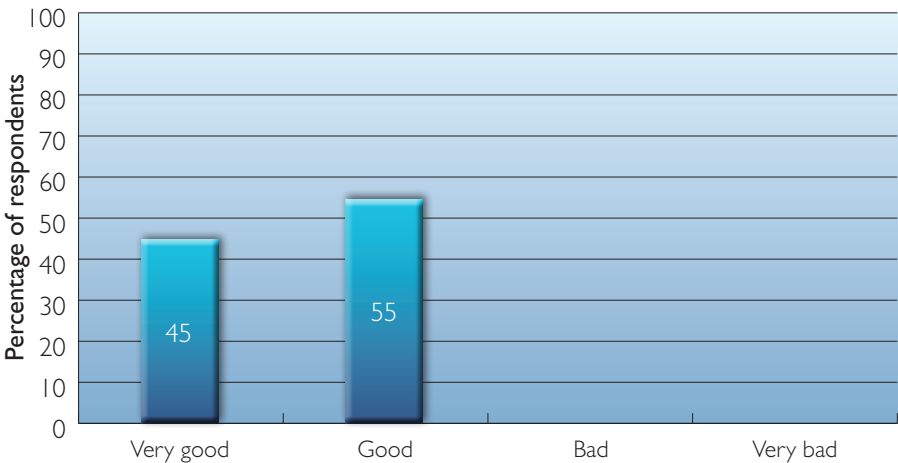


Figure 4. Absorbance capacity rating for Mepilex Border.

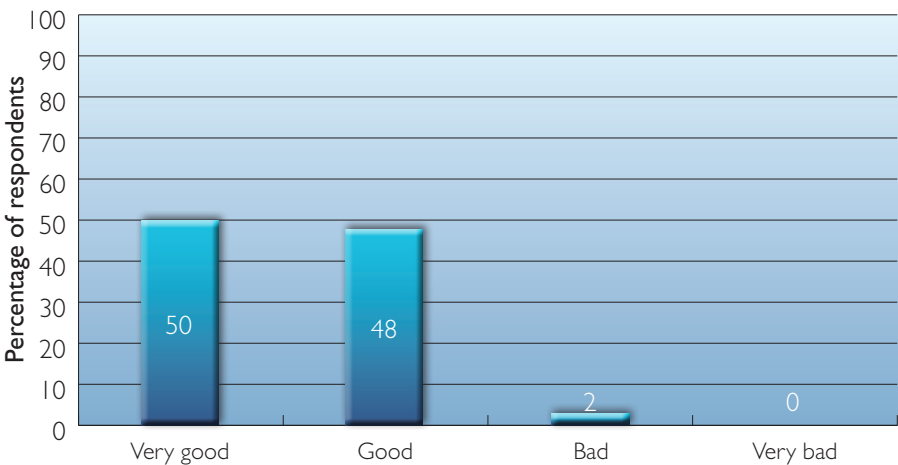

Figure 5. Elasticity rating for Mepilex Border.

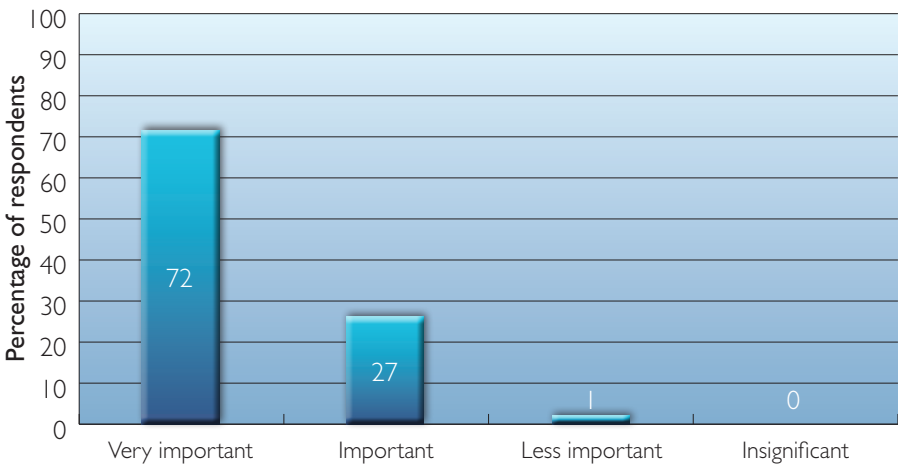


Figure 6. The survey respondents' opinions on the importance of dressing elasticity for the maintenance of healthy peri-wound skin.

However, these dressings do not provide an optimal healing environment; they are inefficient at managing wound exudate and are painful to remove (Hollinworth and Collier, 2000). In addition, adherent secondary dressings

are not recommended for use on surgical wounds as they can increase the risk of mechanical damage to the wound upon removal, e.g. skin stripping and blistering, thereby creating an entry site for bacterial contamination (Chrintz et al, 1989).

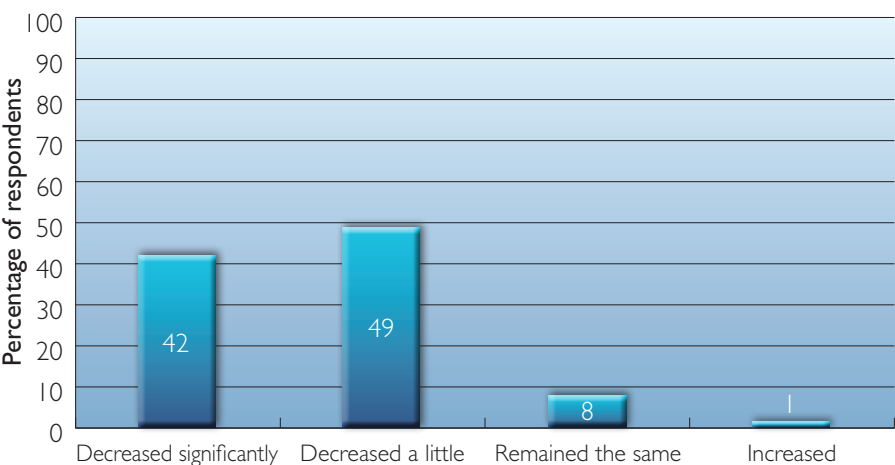


Figure 7. The survey respondents' opinion on the occurrence of peri-wound skin reactions following the introduction of Mepilex Border.

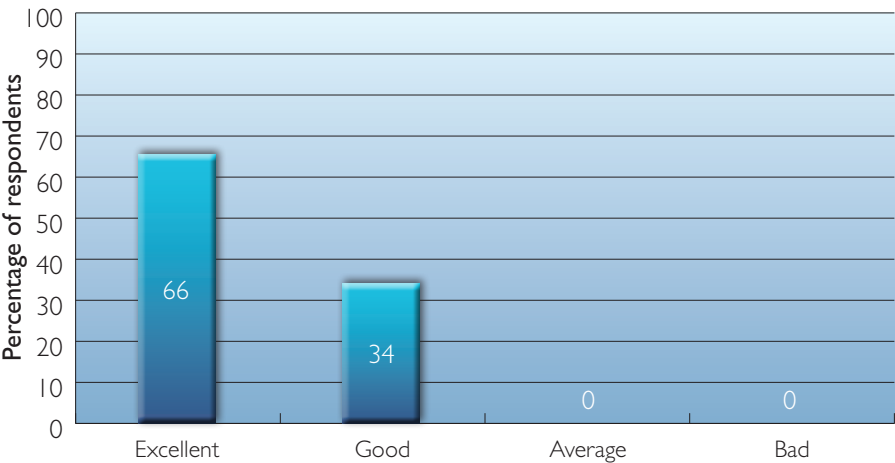


Figure 8. The survey respondents' overall experience of using Mepilex Border.

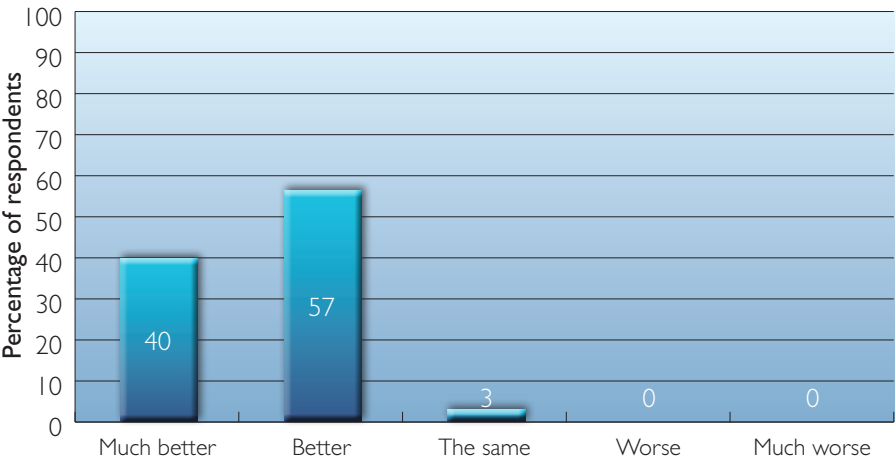


Figure 9. The survey respondents' overall performance rating for Mepilex Border.

Several clinical evaluations have demonstrated that dressings with Safetac technology are beneficial in the management of surgical wounds and their complications. In one non-randomised study, a soft silicone wound contact

dressing compared favourably to other non-adherent wound contact layers in terms of ease of dressing removal and patient comfort (Burton, 2004).

Safetac technology also proved

an effective pressure dressing for post-operative amputation wounds, resolving trauma and pain over the amputation stump and resulting in fewer complications than with conventional elastic bandages (Gleaves and Eldridge, 2004).

A subsequent series of case studies found that an absorbent foam dressing incorporating Safetac facilitated the wound healing of dehisced amputation wounds — conventional dressings are normally difficult to apply to these types of wounds (Weaver and Crawford, 2007).

Finally, a thinner variant of the dressing used in this study (Mepilex® Border Lite [Mölnlycke Health Care]) helped prevent the development of post-operative blisters in patients undergoing oncology-related breast and reconstructive surgery (Meuleneire et al, 2008).

Prior to this, more than 80% of patients experienced post-operative skin lesions as a result of poor dressing choices. In contrast, none of the patients treated with Mepilex Border Lite developed even minor blisters around the post-operative wound. The removal of Mepilex Border Lite did not cause pain or further trauma, and patients provided positive reports on its comfort (Meuleneire et al, 2008).

The findings of the study reported in this article further demonstrate the suitability of dressings with Safetac® adhesive technology. The dressing's 'all-in-one' design, coupled with its ease of application and removal were considered highly beneficial, especially in comparison to the combination dressings previously available for exuding surgical wounds.

Absorbency

The amount of exudate encountered by the nurses in this survey ranged from minimal post-operative serous leakage to moderate exudate. The results demonstrate that Mepilex Border has an excellent absorbance capacity.

This supports the findings of a study comparing Mepilex Border with another commercially available soft silicone foam dressing, which found that Mepilex



Border has good exudate management properties in terms of absorbency and fluid retention, both before and after the application of pressure (Davies and Rippon, 2009).

The nurses who took part in this study recognised the importance of a dressing's ability to manage exudate for maintaining the health of the peri-wound skin. Poor management of wound exudate or the failure to adequately control moisture balance at the wound-dressing interface can result in excoriation, irritant dermatitis and/or maceration of peri-wound skin (Cutting and White, 2002).

The seal formed between intact skin and a Safetac dressing inhibits the lateral movement of exudate from the wound onto the surrounding area, thereby helping to prevent maceration of the peri-wound region (White 2005).

As stated earlier, post-operative blistering is a common complication of surgical wounds. The evidence in the

literature supports a link between a lack of dressing elasticity and post-operative wound oedema, leading to the formation of tension blisters at the skin-dressing interface (Blaylock et al, 1995).

Friction can also occur when a patient moves, creating mechanical stress between the wound dressing and the skin (Koval et al, 2003 ). This is particularly apparent when a surgical wound is located around a joint (e.g. shoulder; hip or knee) (Hahn et al, 1999; Gupta et al, 2002; Koval et al, 2003; Ravenscroft et al, 2006). The elastic properties of Mepilex Border identified in this survey suggest that dressings with Safetac adhesive technology can overcome this complication, as the micro-adherent property of the soft silicone reduces the mechanical shear forces between the dressing and the skin.

Indeed, 91% of the nurses surveyed noticed a decrease in peri-wound skin reactions following the use of Mepilex Border compared to previous dressing regimens — 42% considered

this decrease to be significant in their professional opinion.

### Limitations



Surveys such as the one reported in this paper, provide reasonable insight into issues relating to clinical practice, such as wound dressing selection (White, 2008).

In this study the participants were asked to subjectively compare the performance of Mepilex Border with that of other dressings they had used previously. While it is likely that wounds treated with other dressings were similar to those treated with Mepilex Border, the possibility of the results being influenced by differences (e.g. exudate levels, bioburden, condition of peri-wound skin) cannot be excluded.

On the whole, the nurses reported a positive experience when using Mepilex Border and based on its overall performance, considered Mepilex Border as a suitable dressing for use in the treatment of surgical wounds. However, further clinical research based



Available on the UK Drug Tariff from 1st April 2010  
Contact KCI Medical Ltd., tel +44 (0) 800 980 8880



Now you can apply the benefits of V.A.C.® Therapy to practically any wound site.  
Where will you use it?

**New V.A.C.® GranuFoam® Bridge Dressing Kit**

# Ready-made for you

See how practical bridging can be:



0800 980 8880



www.kci-medical.com



NOTE: Specific indications, contraindications, warnings, precautions and safety information exist for KCI products and therapies. Please consult a physician and product instructions for use prior to application. ©2009 KCI Licensing, Inc. All rights reserved. All trademarks designated herein are proprietary to KCI Licensing, Inc., its affiliates and/or licensors. Those KCI trademarks designated with the "®" or "™" symbol are either registered or pending registration in at least one country where this product is commercialized, but not necessarily in all such countries. Most KCI products are patented and/or subject to pending patents. DSL#09-10-562.N (10/09)

on objective data, is required to fully assess the benefits of using the dressing on surgical wounds.

## Conclusion

Surgical wounds are created intentionally and the surgeon is able to assess and minimise the risks to healing. Wound healing can be enhanced and wound infections prevented by simple, inexpensive and readily available means. The selection of appropriate wound dressings is an important part of the nurse's wound care strategy.

Thus, dressings that are easy to use and can reduce clinical complications possess obvious benefits, for example, reductions in wound healing times and treatment costs lead to a more efficient use of NHS resources.

The results of this survey demonstrate that nurses found the performance of Mepilex Border superior to dressing regimens they had used in the past. Mepilex Border demonstrates excellent handling properties, is easy to use and is highly conformable. These properties all contribute to an environment conducive to wound healing. **WUK**

## References

- Abuzakuk TM, Coward P, Shenava Y et al (2006) The management of wounds following primary lower limb arthroplasty: a prospective, randomised study comparing hydrofibre and central pad dressings. *Int Wound J* 3(2): 133–7
- Baxter H (2003) Management of surgical wounds. *Nurs Times* 99(13): 66–8
- Blaylock B, Murray M, O'Connell K, Rex J (1995) Tape injury in the patient with total hip replacement. *Orthopaedic Nurs* 14(3): 25–8
- Burton F (2004) An evaluation of non-adherent wound-contact layers for acute traumatic and surgical wounds. *J Wound Care* 13(9): 371–3
- Chrintz H, Vibits H, Cordtz TO, et al (1989) Need for surgical wound dressing. *Br J Surg* 76(2): 204–5
- Cosker T, Elsayed S, Gupta S, Mendonca AD, Tayton KJJ (2005) Choice of dressing has a major impact on blistering and healing outcomes in orthopaedic patients. *J Wound Care* 14(1): 27–9
- Cutting KF (2008) Impact of adhesive surgical tape and wound dressings on the skin, with particular reference to skin stripping. *J Wound Care* 17(4): 157–62
- Cutting KF, White RJ (2002) Maceration of the skin I: the nature and causes of skin maceration. *J Wound Care* 11(7): 275–8
- Davies P, Rippon M (2009) Mepilex Border: a monograph. Medical Communications UK, Holsworthy
- Dealey C (1994) *The Care of Wounds*. Blackwell Science, Oxford
- Dykes PJ, Heggie R, Hill SA (2001) Effects of adhesive dressings on the stratum corneum of skin. *J Wound Care* 10(2): 7–10
- Foster L, Moore P (1997) The application of a cellulose-based fibre dressing in surgical wounds. *J Wound Care* 6(10): 469–73
- Gleaves JR, Eldridge K (2004) Silicone sheeting as alternative to elastic bandages in dressing lower extremity amputations. *Ostomy Wound Manage* 50(9): 8–10
- Gupta SK, Lee S, Moseley LG (2002) Postoperative wound blistering: is there a link with dressing usage? *J Wound Care* 11(7): 271–3
- Hahn GJ, Grant D, Bartke C, et al (1999) Wound complications after hip surgery using a tapeless compressive support. *Orthopaedic Nurs* 18(3): 43–9
- Hollinworth H, Collier M (2000) Nurses' views about pain and trauma at dressing changes: results of a national survey. *J Wound Care* 9(8): 369–73
- Jester R, Russell L, Fell S, Williams S, Prest C (2000) A one hospital study of the effect of wound dressings and other related factors on skin blistering following total hip and knee arthroplasty. *J Orthopaedic Nurs* 4(2): 71–7
- Koval K, Egol K, Polatsch D, Baskies M, Homman JP, Hiebert RN (2003) Tape blisters following hip surgery. *J Bone Joint Surg Am* 85: 1884–7
- Lawrentschuk N, Falkenberg MP, Pirpiris M (2002) Wound blisters post hip surgery: a Prospective trial comparing dressings ANZ J Surg 72(10): 716–19
- Marks J, Harding K, Ribeiro C (1985) Pilonidal sinus excision in healing by open granulation. *Br J Surg* 72: 637–40
- Meuleneire F, Mulier P, Fostier A, Goossens K (2008) Introduction of a New Procedure for Preventing Skin Lesions after Oncologic Breast Surgery. Poster presentation at the 3rd Congress of the World Union of Wound healing Societies, Toronto, Canada
- National Institute for Health and Clinical Excellence (2008) Surgical Site Infection: prevention and treatment of surgical site infection. NICE, London. Available online at: [www.nice.org.uk/nicemedia/pdf/](http://www.nice.org.uk/nicemedia/pdf/)
- Ravenscroft MJ, Harker J, Buch KA (2006) A prospective, randomised, controlled trial comparing wound dressings used in hip and knee surgery: Aquacel and Tegaderm versus Cutiplast. *Ann R Coll Surg Engl* 88: 18–22
- Rippon MG, White R (2007) Adhesive Wound Dressing Function in vivo: the role of micro-adherence in optimum performance. Poster presentation at the European Wound Management Association Conference, Glasgow, UK, 2–4 May
- Vermeulen H, Ubbink D, Goossens A, et al (2007) Dressings and topical agents for surgical wounds healing by secondary intention. *Cochrane Database Syst Rev* 2: CD003554
- Weaver G, Crawford K (2007) The use of Mepilex on dehiscent amputation wounds. *Wounds UK* 3(1): 70–4
- White RJ (2005) Evidence for atraumatic soft silicone wound dressing use. *Wounds UK* 1(3): 104–9
- White R (2008) A multinational survey of the assessment of pain when removing dressings. *Wounds UK* 4(1): 14–22
- Wright M (1994) Hip blisters. *Nurs Times* 90(16): 86–8

## Key points

- ▶ Surgical wound management should aim to minimise trauma to the wound and surrounding skin, prevent microbial invasion and promote patient comfort.
- ▶ Dressings utilising traditional adhesives can cause trauma to the wound, skin stripping and blistering, all of which can delay healing and increase treatment costs.
- ▶ Mepilex Border® is a dressing designed to prevent trauma and minimise pain at dressing change.
- ▶ This survey of nurses found the performance of Mepilex Border to be superior to previous dressing regimens when used on post-operative wounds.

CG74FullGuideline.pdf [accessed 21 January 2010]